



Cardiac manifestations of *Staphylococcus aureus* infection in children

Shenaaz Hoosain

Fellow in Paediatric Cardiology

CHBAH/NMCH



Introduction



- *Staphylococcus aureus* infections
- Appropriate anti-staphylococcal antibiotics
- High morbidity and mortality rate
- Cardiac complications !!!
 - Infective endocarditis
 - Purulent pericarditis

Case Series



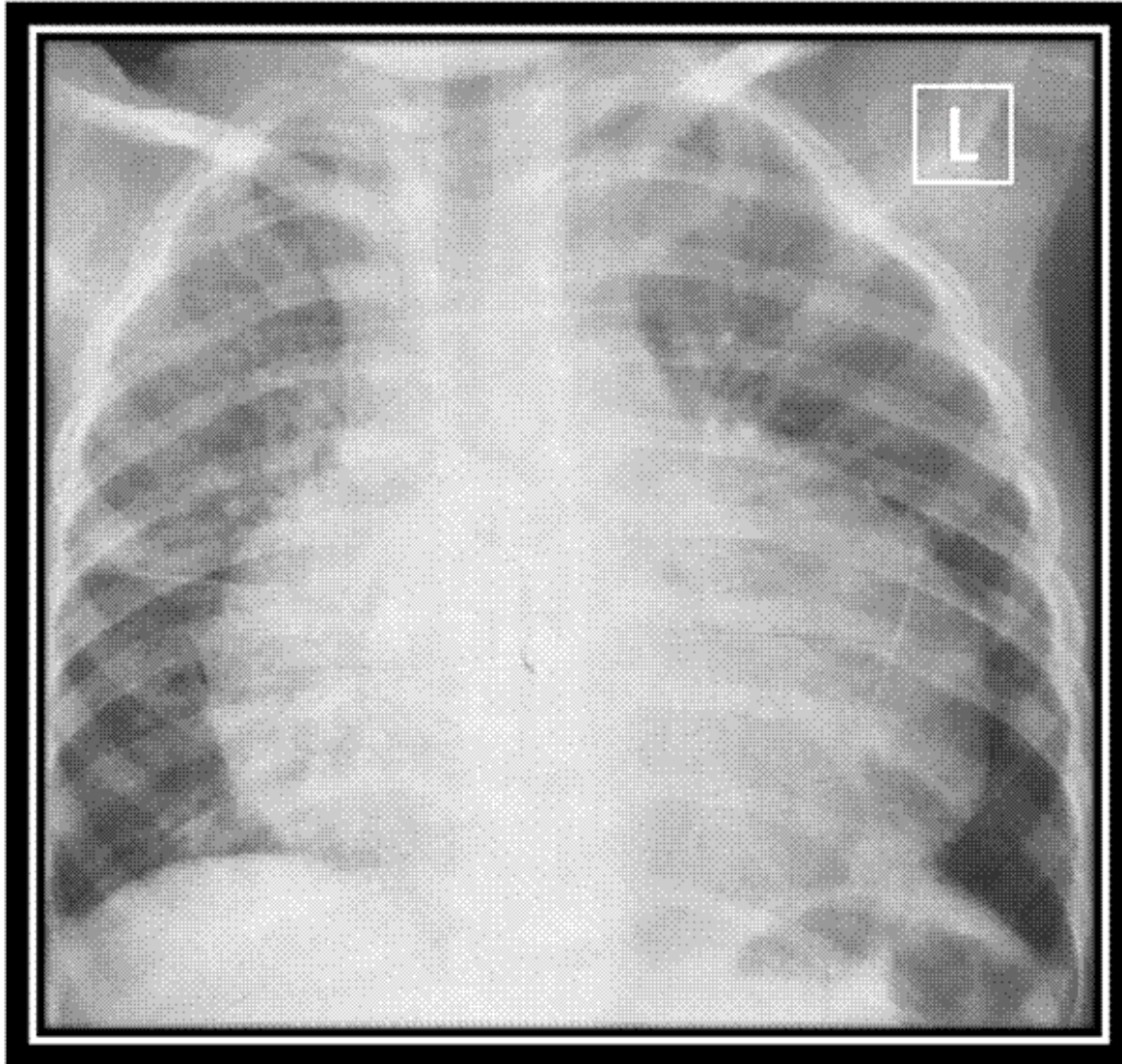
	WO	KN	SM
Age	4 years	19 months	8 years
Gender	Male	Male	Male
Co - morbidities	None	None	None
Presentation	Soft tissue injury left thigh	Soft tissue injury right ankle	Soft tissue injury left ankle
Diagnosis	Septic arthritis Osteomyelitis	Septic arthritis Osteomyelitis	Septic arthritis Osteomyelitis
Bacteraemia	Methicillin sensitive <i>Staphylococcus aureus</i>		

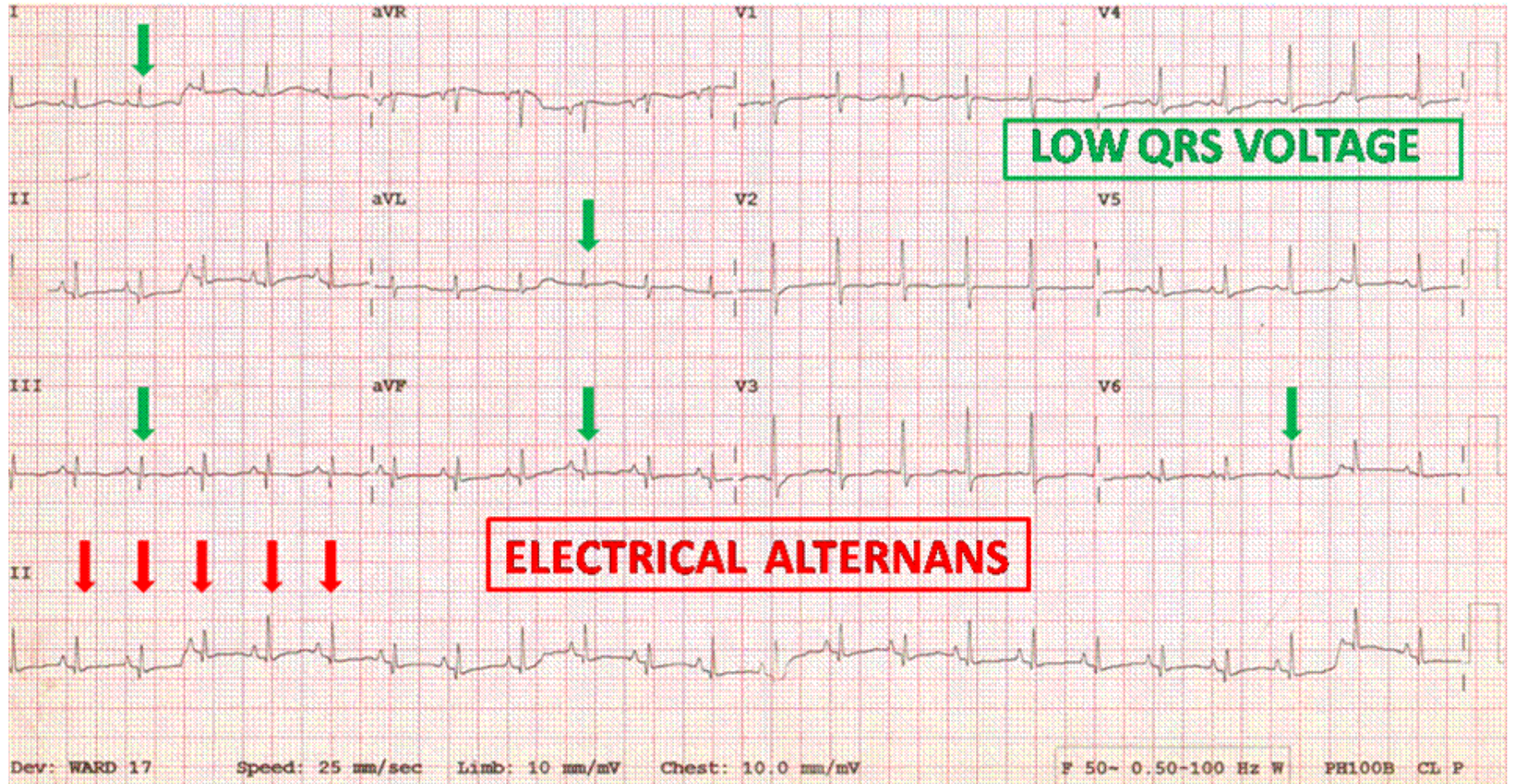
Case Series

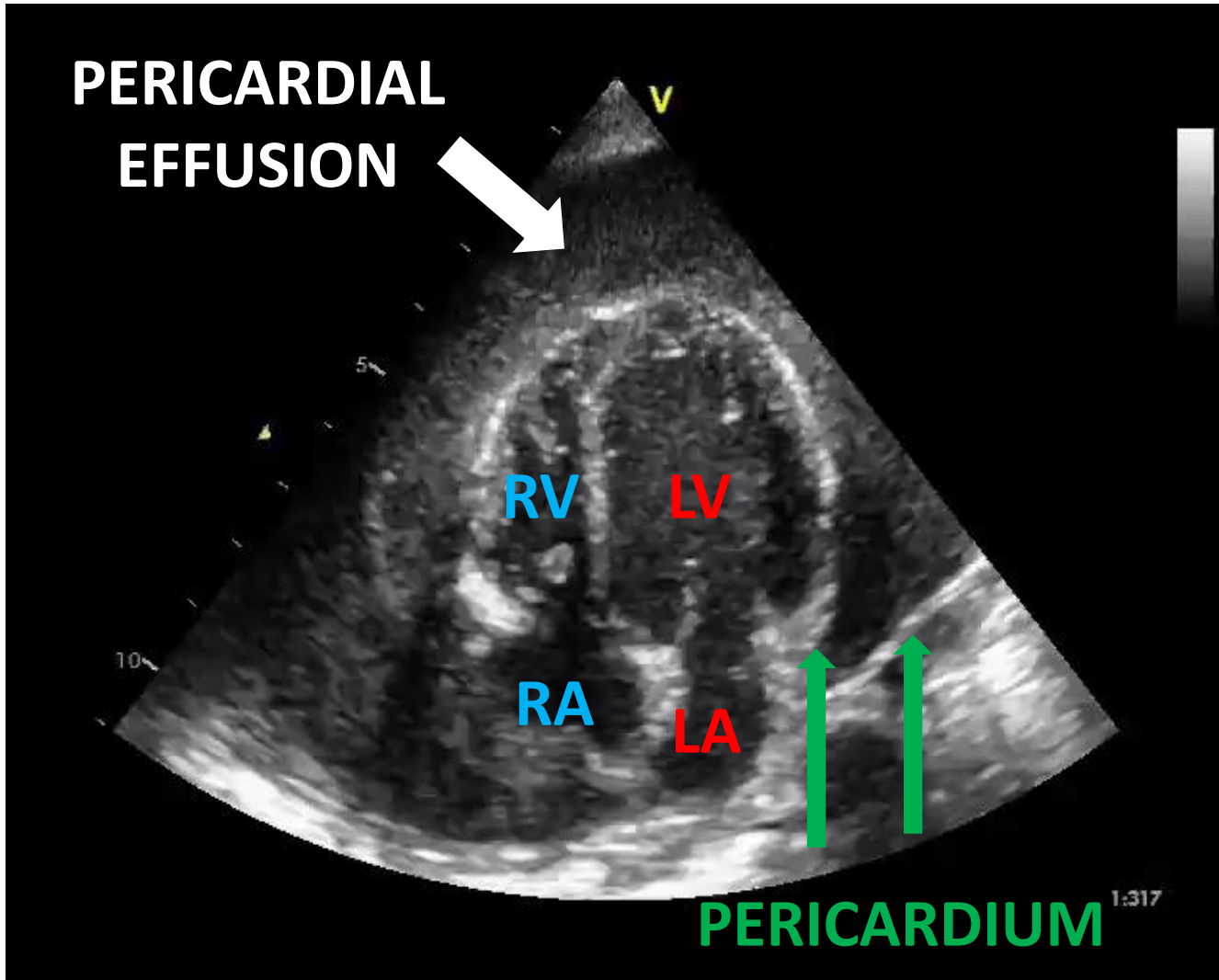


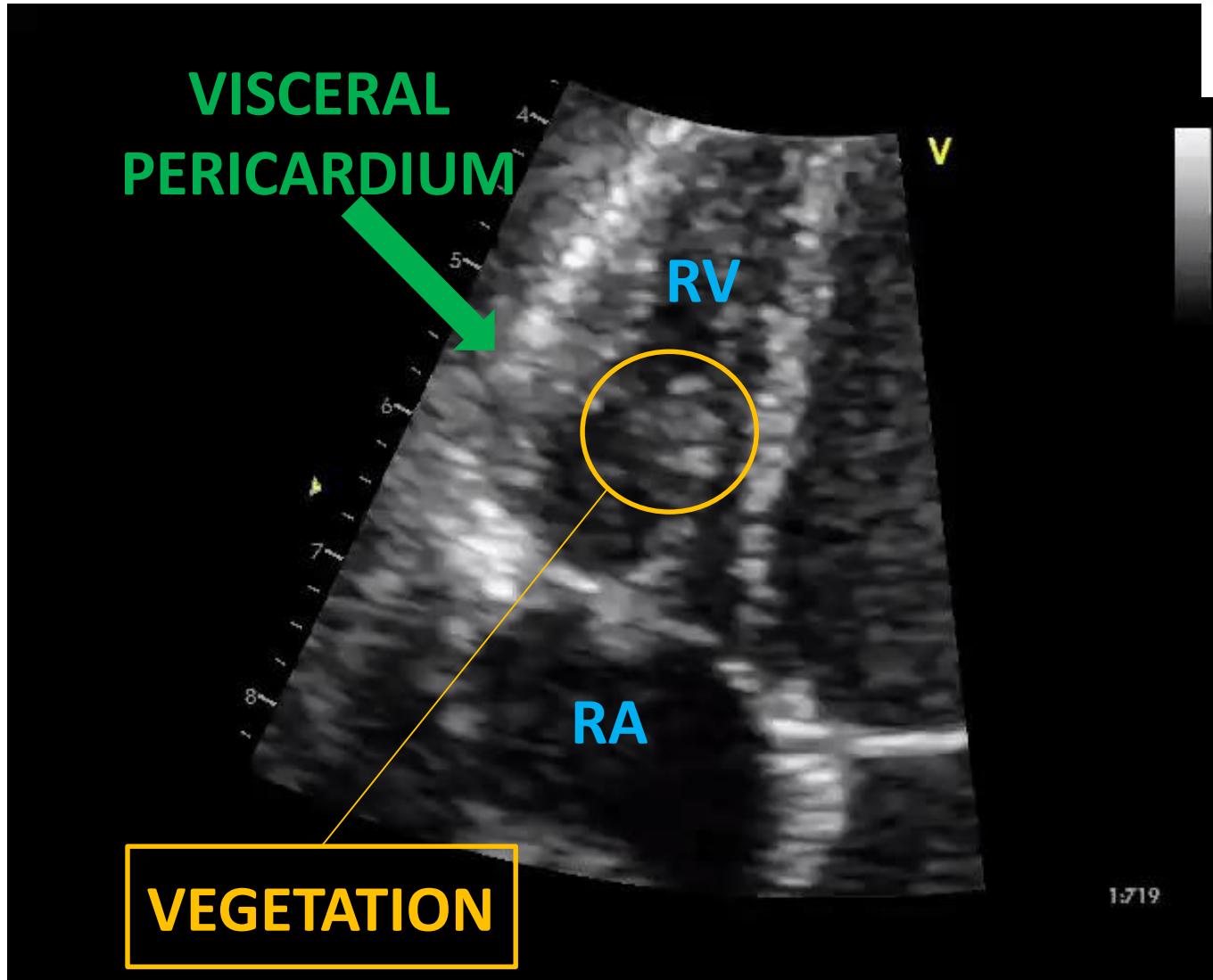
	WO	KN	SM
Age	4 years	19 months	8 years
Gender	Male	Male	Male
Co - morbidities	None	None	None
Presentation	Soft tissue injury left thigh	Soft tissue injury right ankle	Soft tissue injury left ankle
Diagnosis	Septic arthritis Osteomyelitis	Septic arthritis Osteomyelitis	Septic arthritis Osteomyelitis
Bacteraemia	Methicillin sensitive <i>Staphylococcus aureus</i>		

Case 1: WO







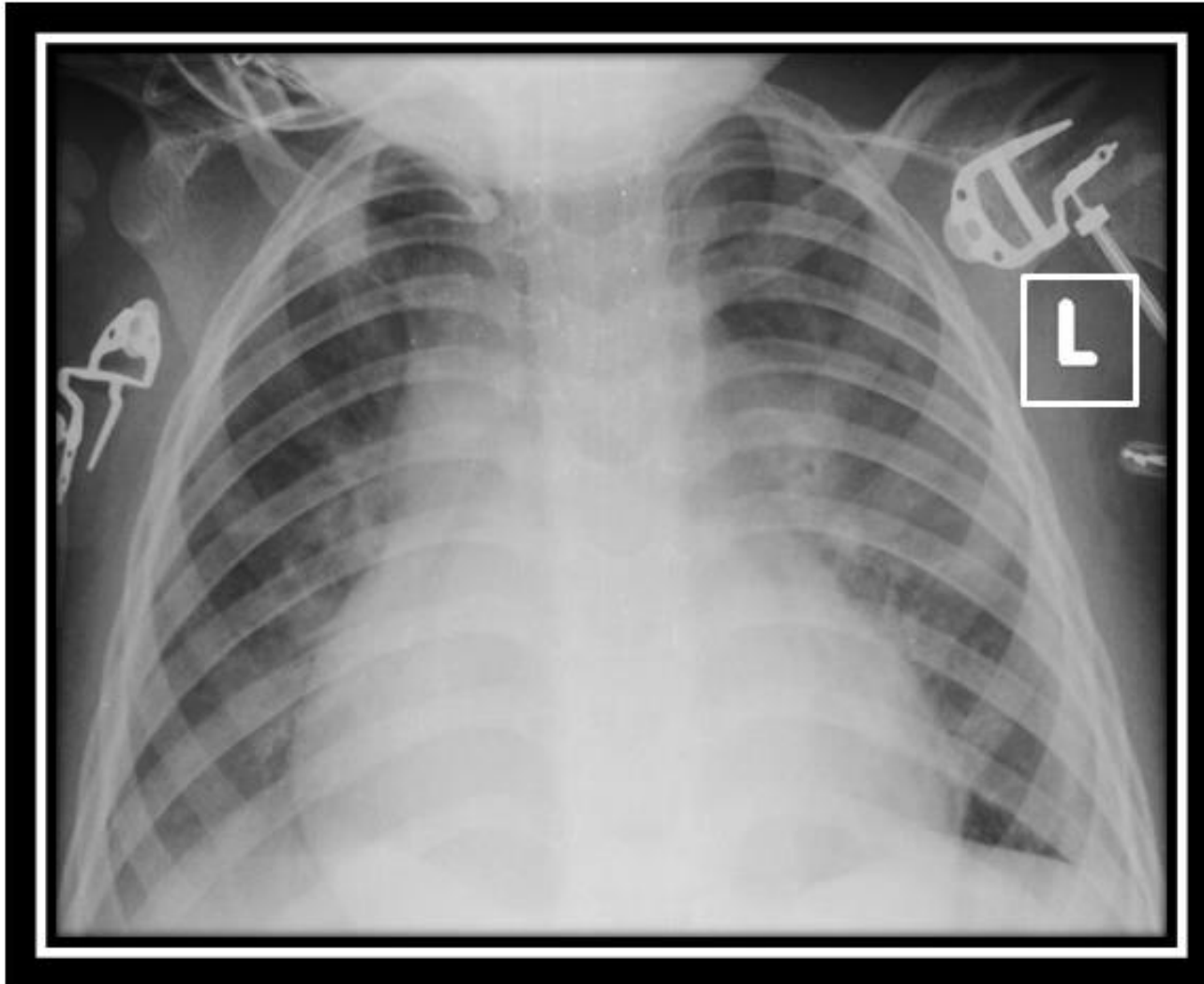


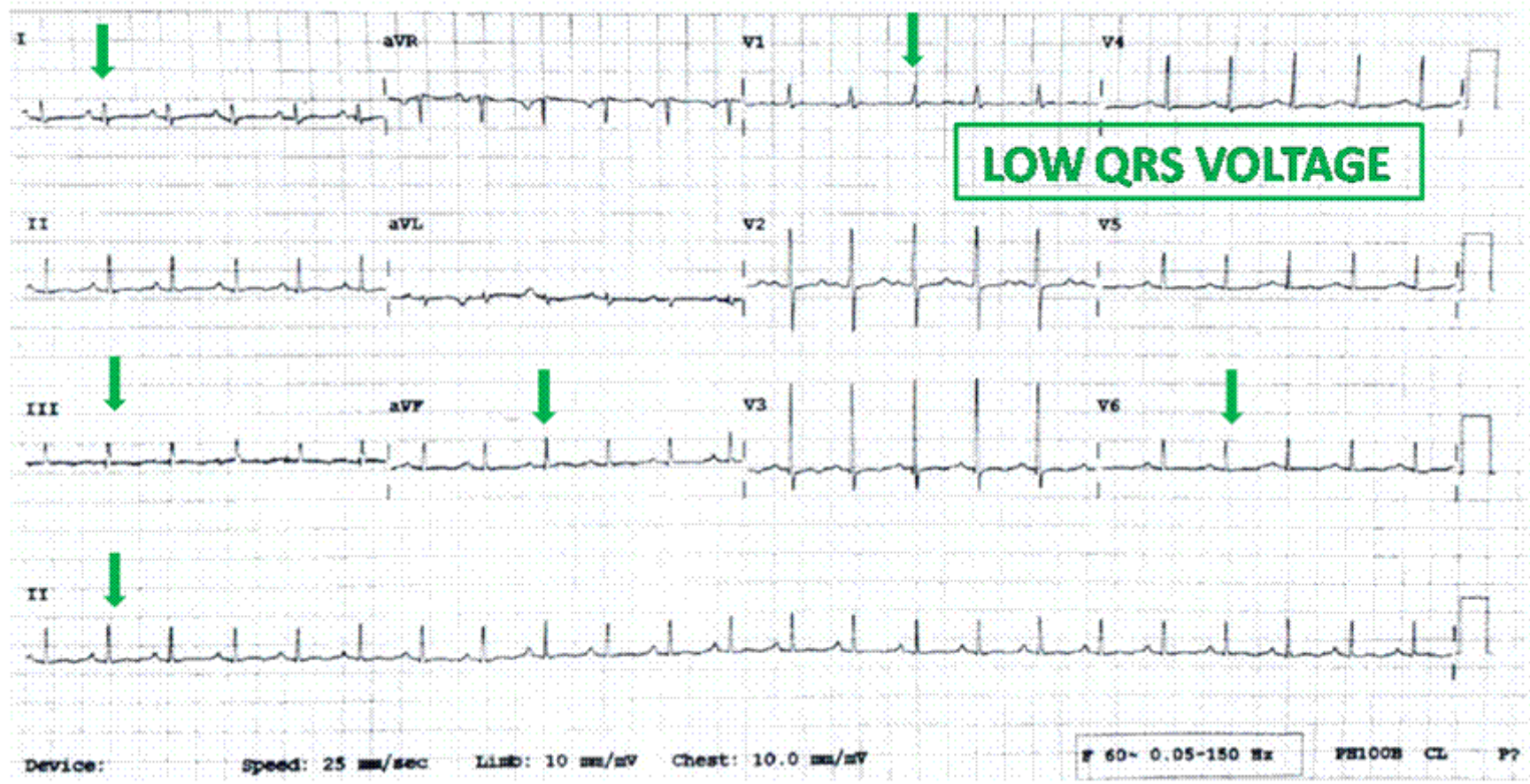
Case Series

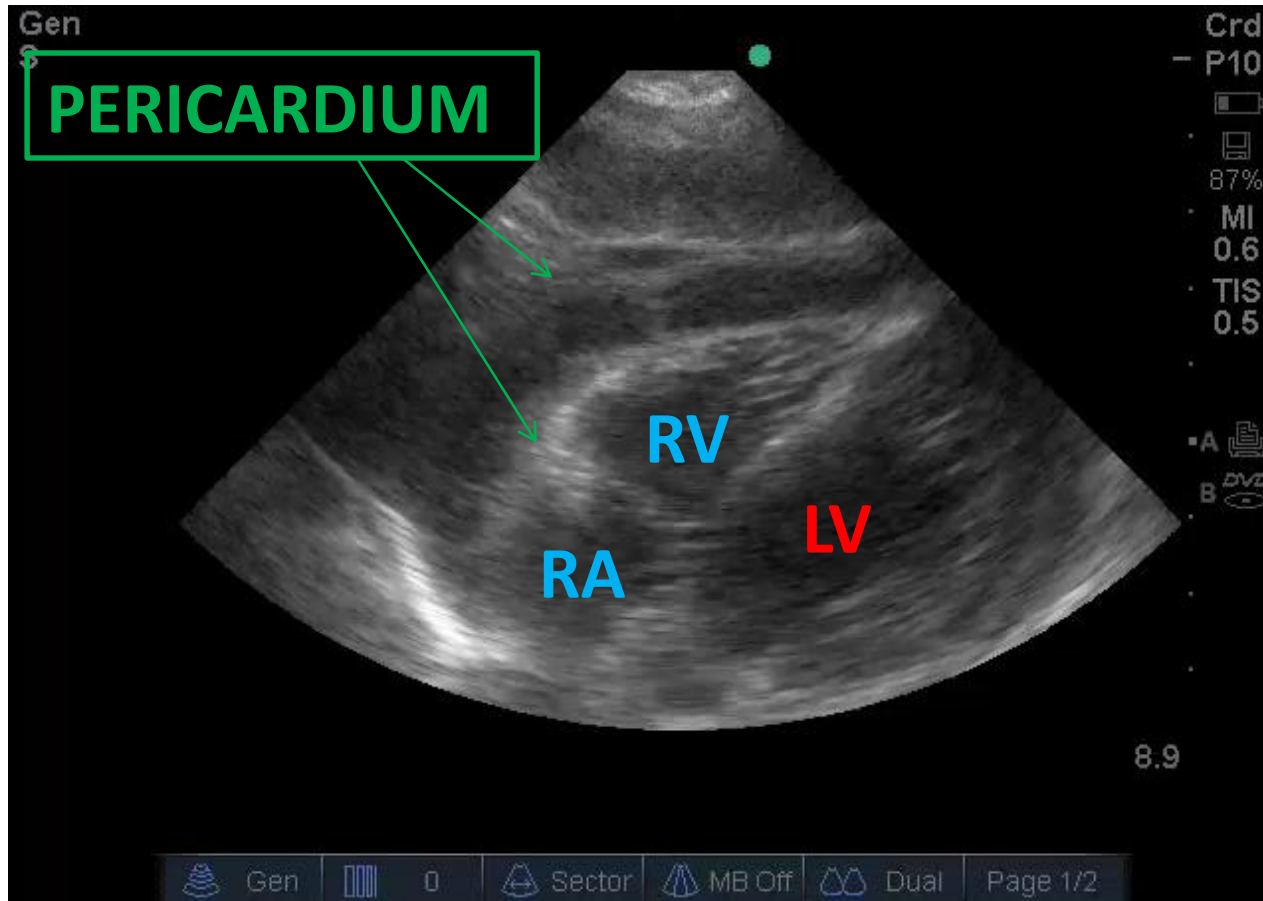


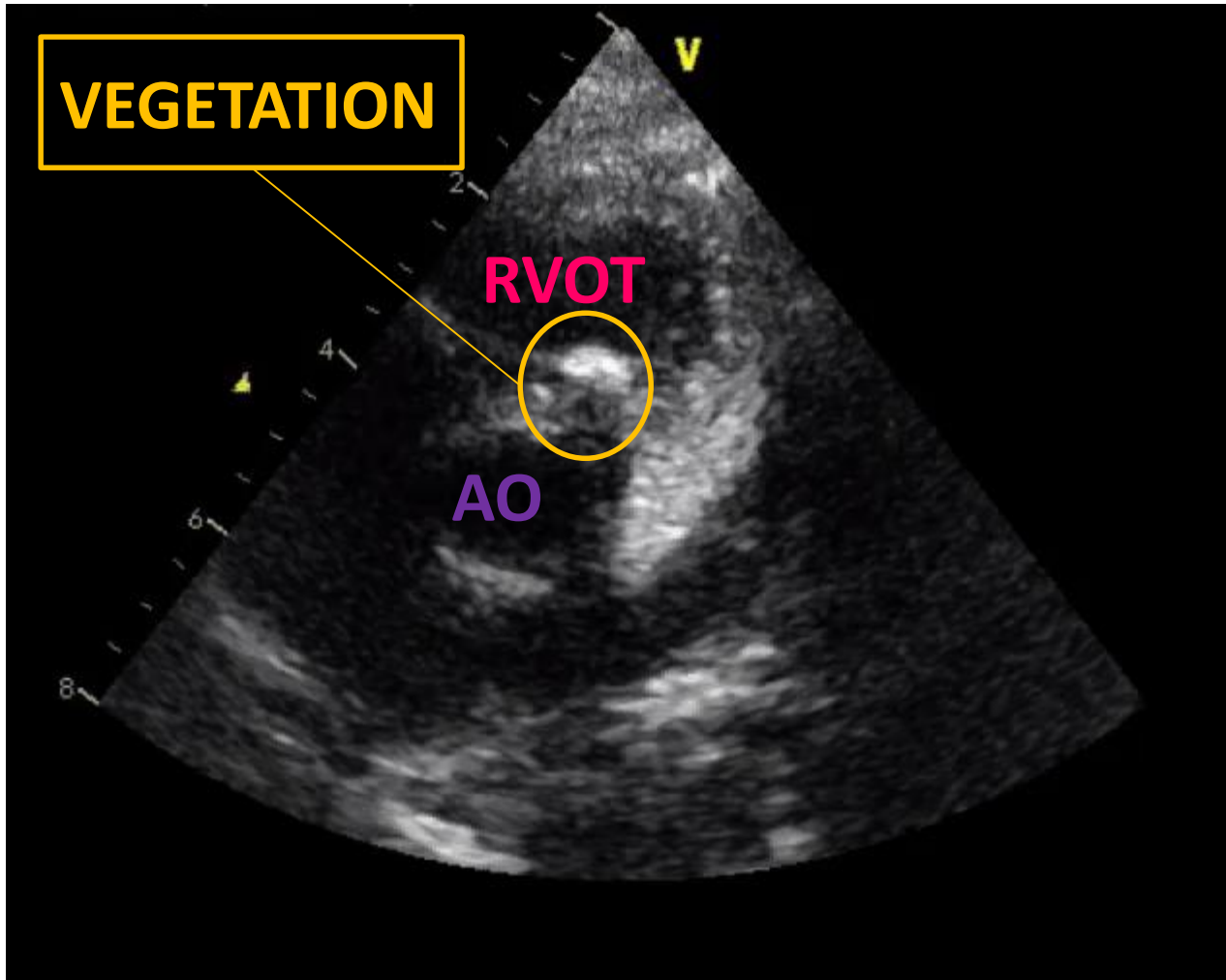
	WO	KN	SM
Age	4 years	19 months	8 years
Gender	Male	Male	Male
Co - morbidities	None	None	None
Presentation	Soft tissue injury left thigh	Soft tissue injury right ankle	Soft tissue injury left ankle
Diagnosis	Septic arthritis Osteomyelitis	Septic arthritis Osteomyelitis	Septic arthritis Osteomyelitis
Bacteraemia	Methicillin sensitive <i>Staphylococcus aureus</i>		

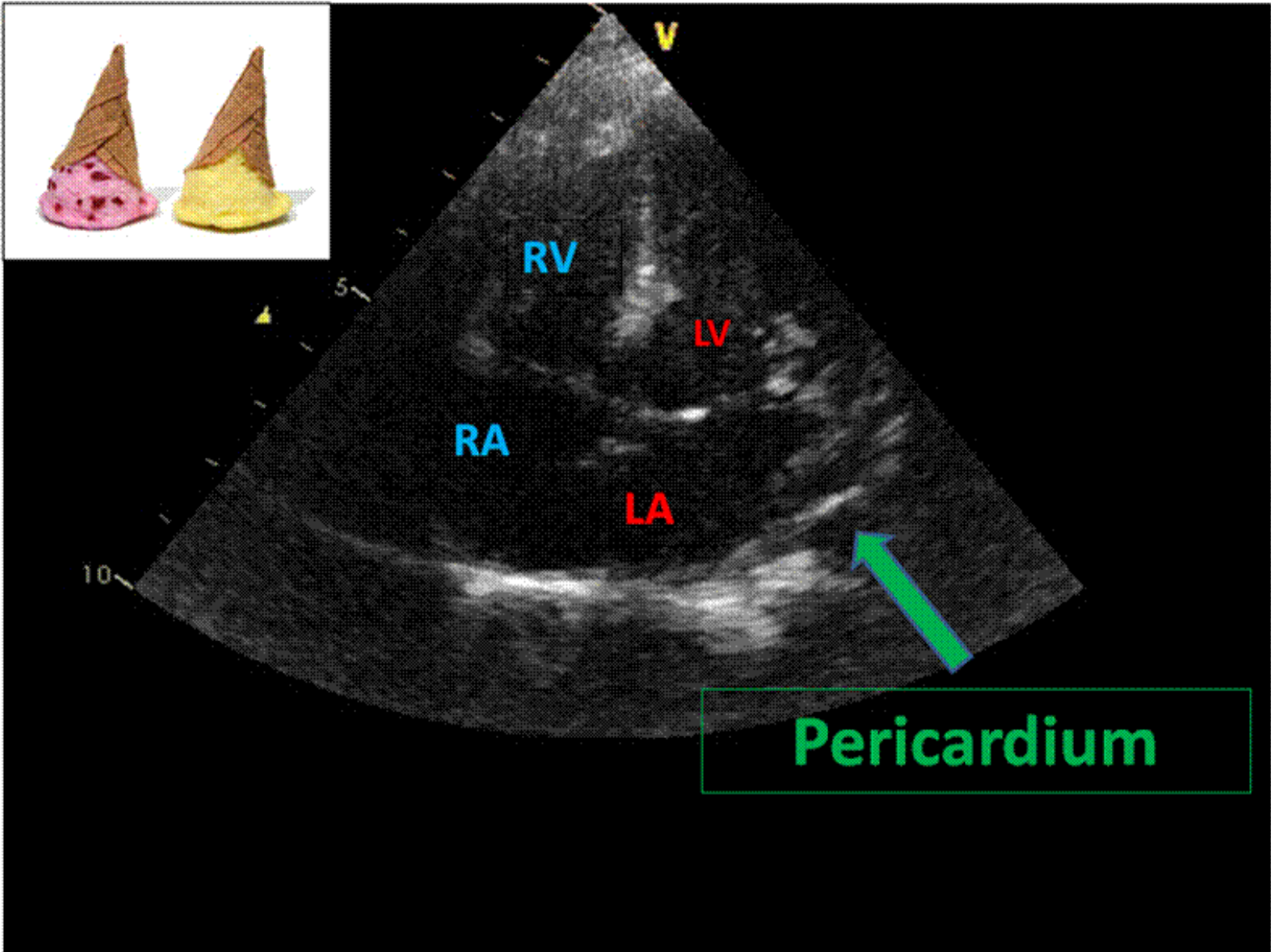
Case 2: KN









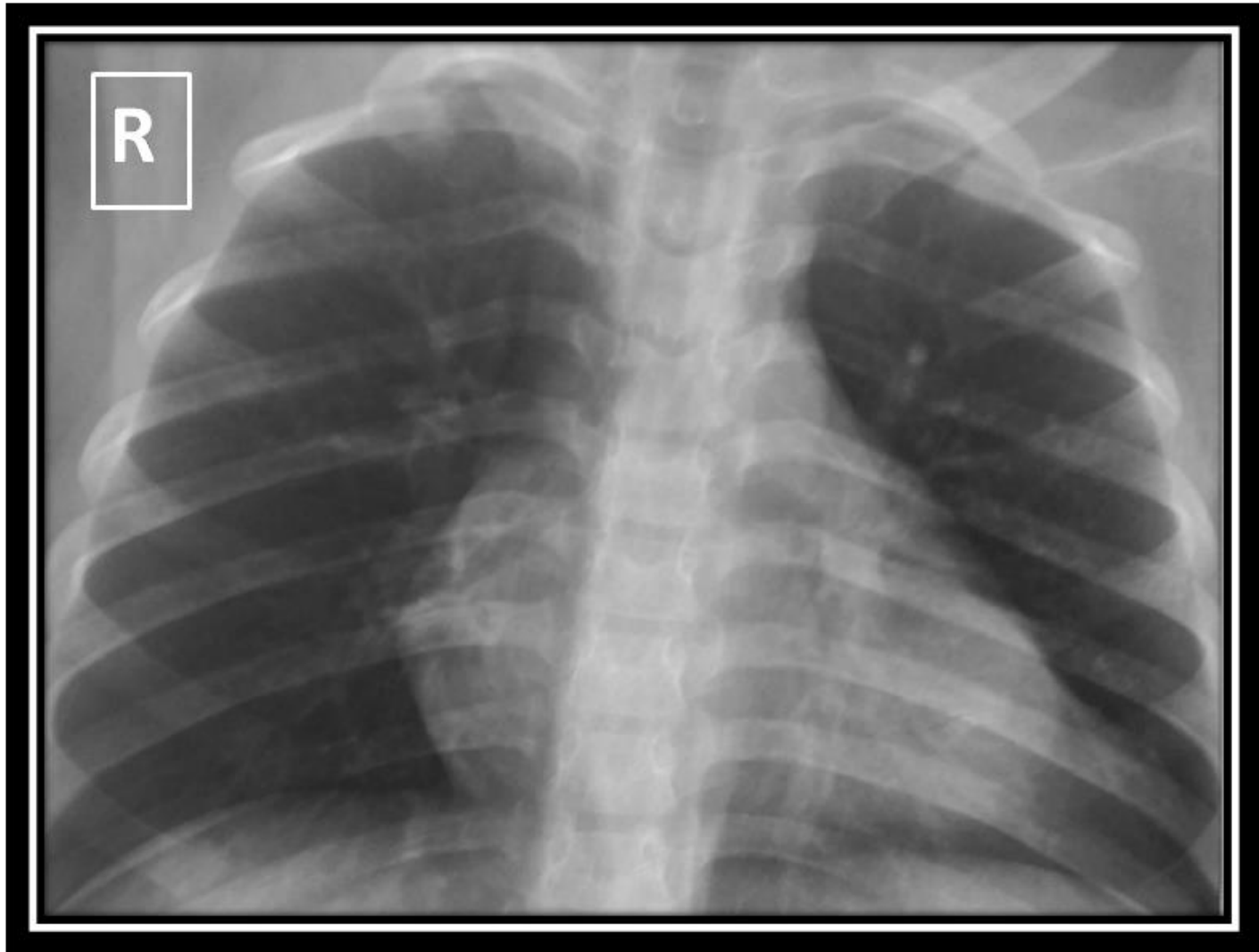


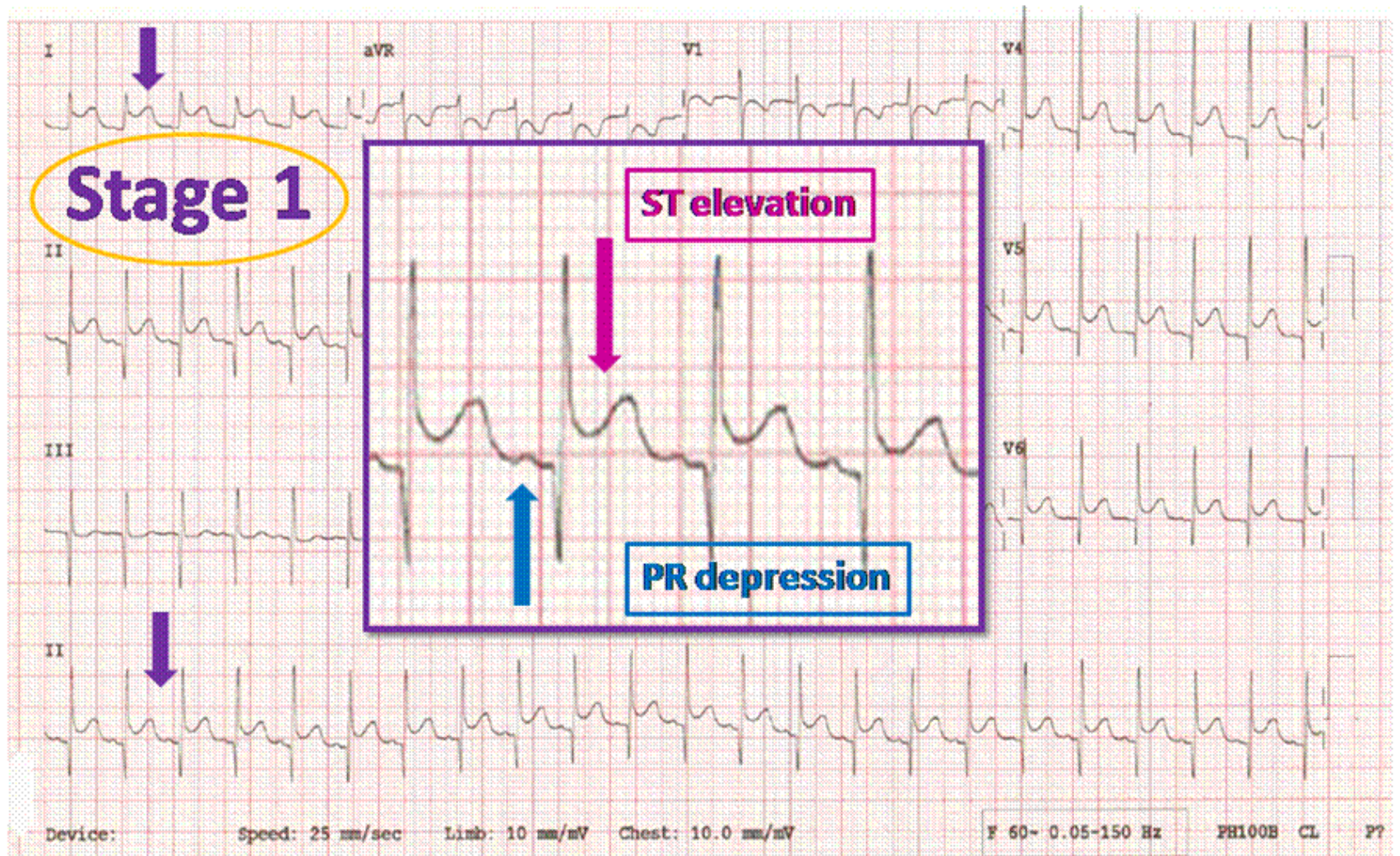
Case Series

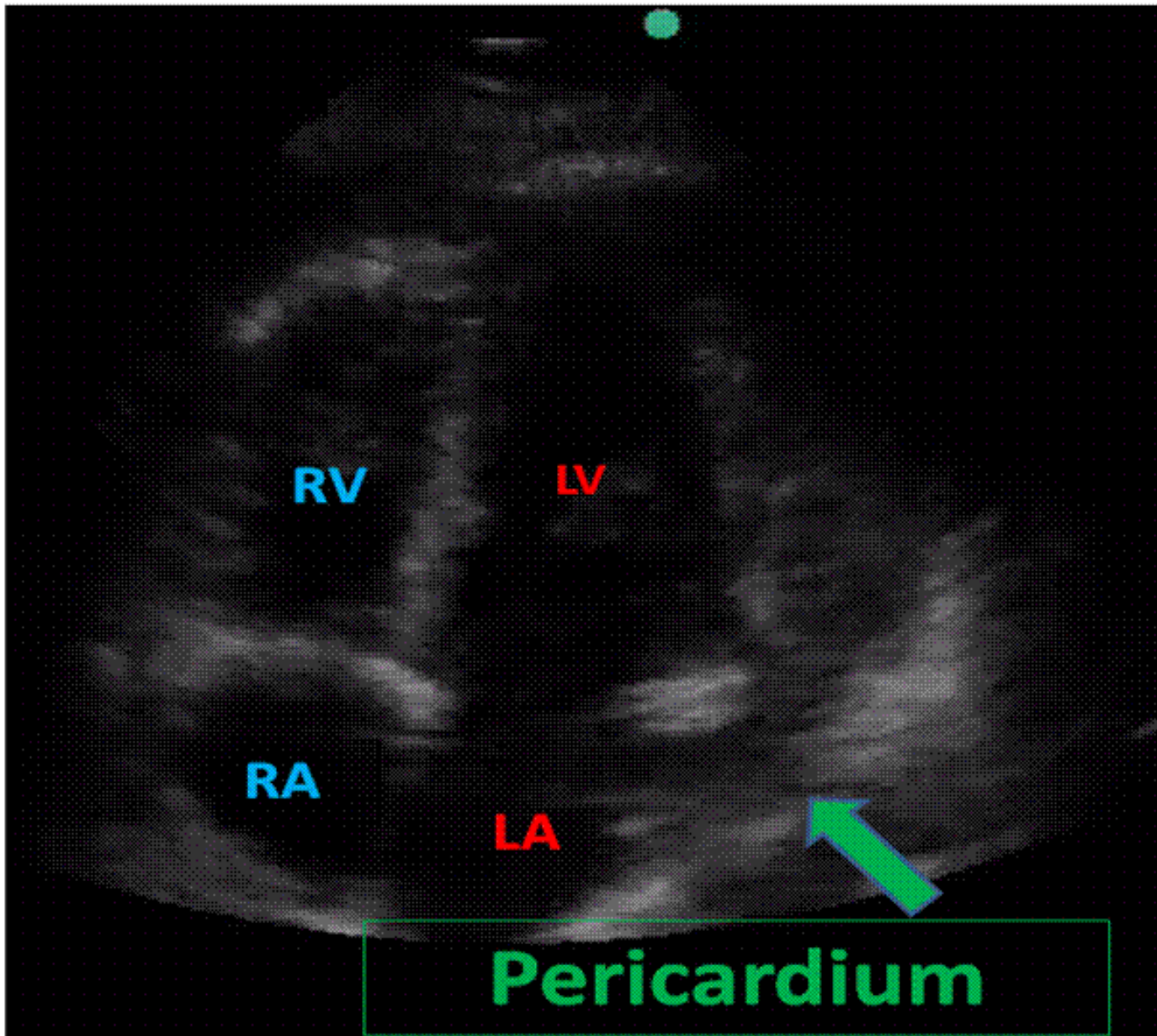


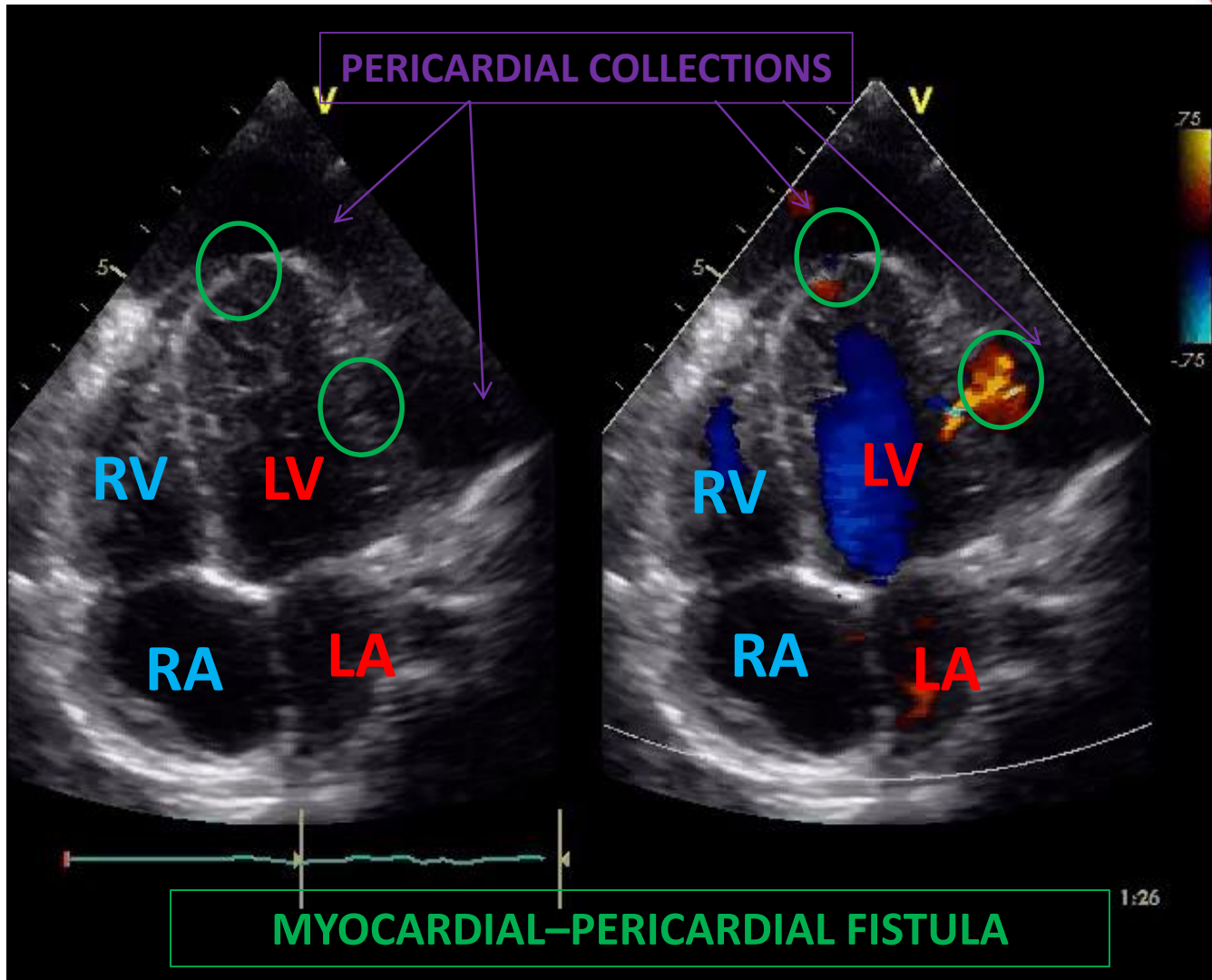
	WO	KN	SM
Age	4 years	19 months	8 years
Gender	Male	Male	Male
Co - morbidities	None	None	None
Presentation	Soft tissue injury left thigh	Soft tissue injury right ankle	Soft tissue injury left ankle
Diagnosis	Septic arthritis Osteomyelitis	Septic arthritis Osteomyelitis	Septic arthritis Osteomyelitis
Bacteraemia	Methicillin sensitive <i>Staphylococcus aureus</i>		

Case 3: SM










Conclusion



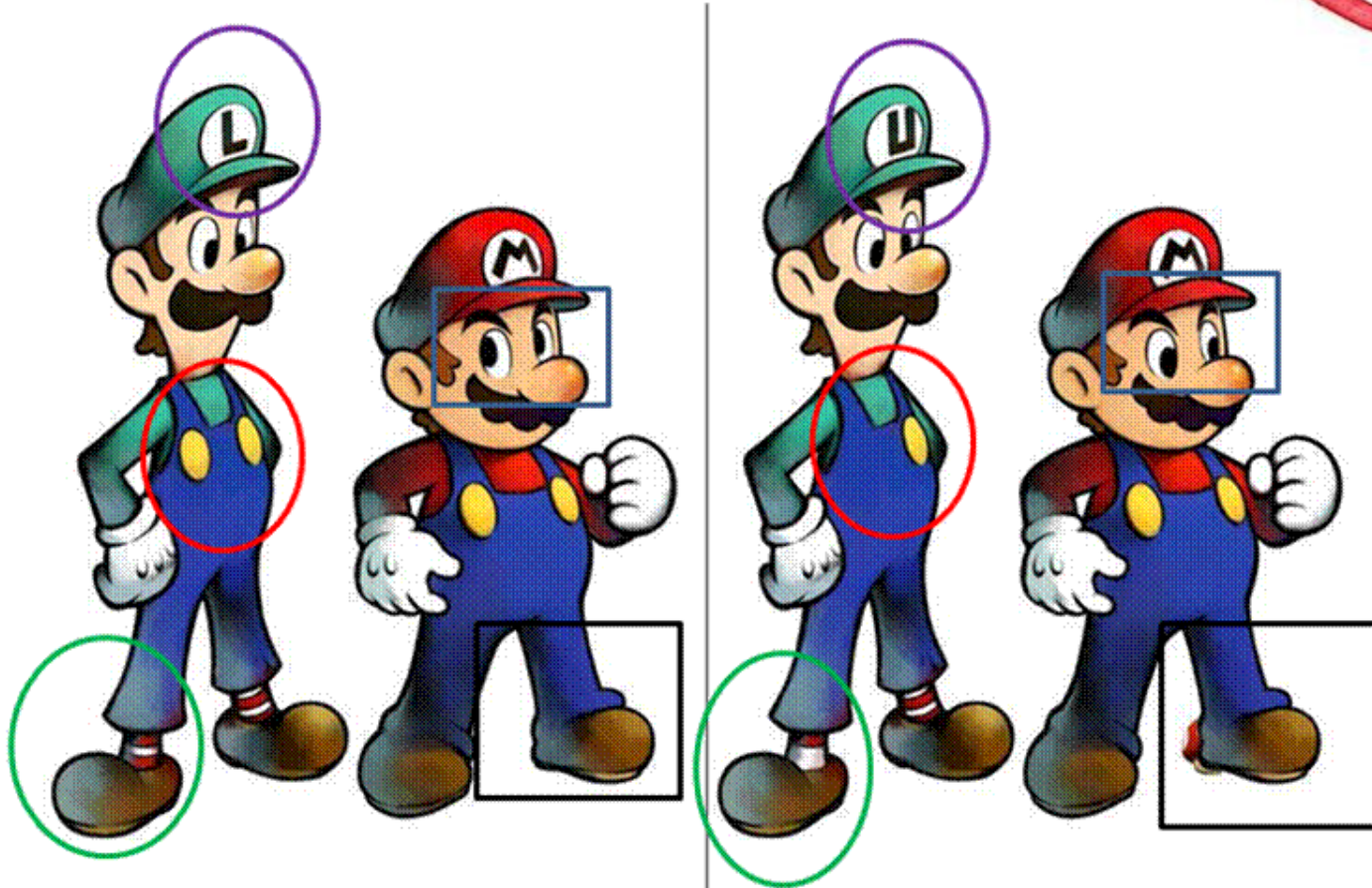
So similar, yet so different



- *Staphylococcus aureus* infection and its devastating consequences
- High index of suspicion for cardiac complications

SPOT THE DIFFERENCE

Thank you



Acknowledgements:

Prof A Cilliers

Dr H Ntsinjana