

Mechanical valve thrombosis in pregnancy

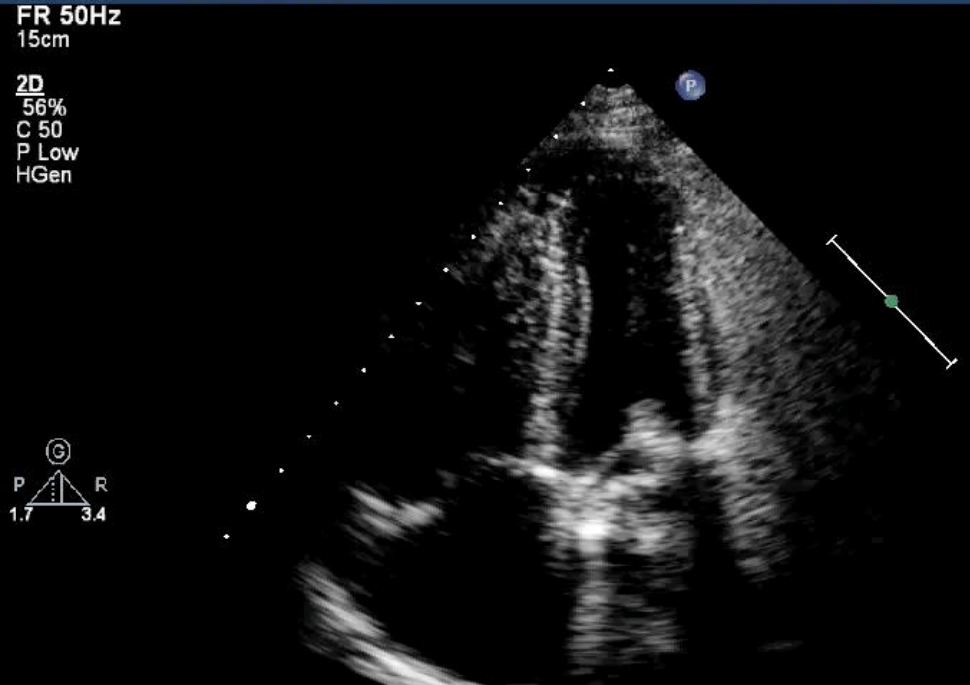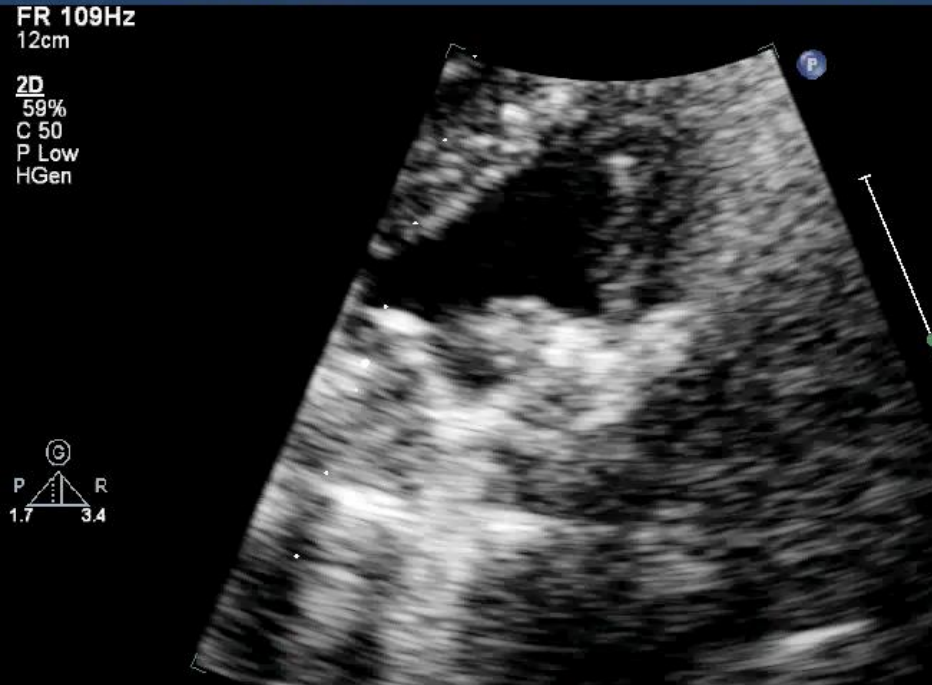
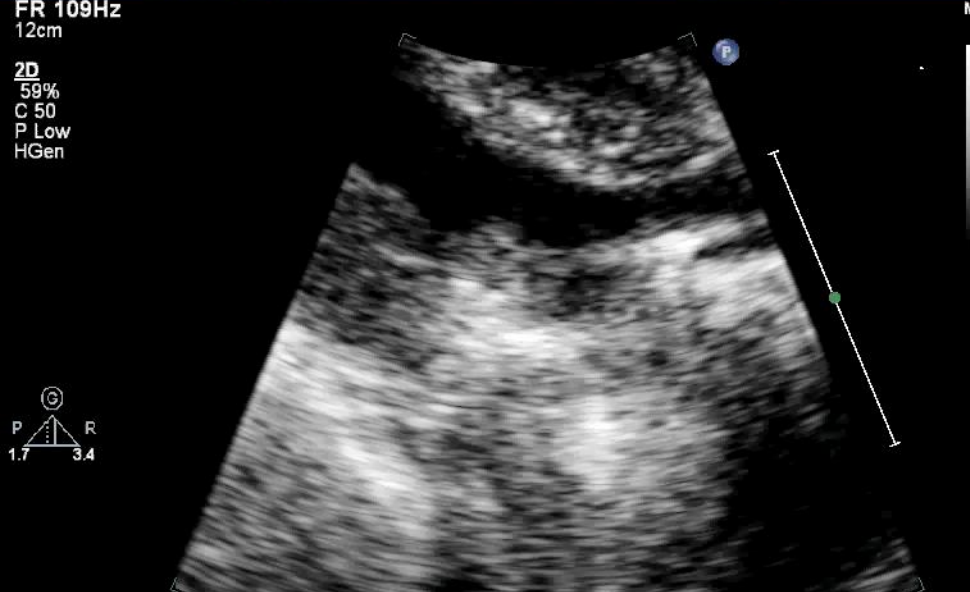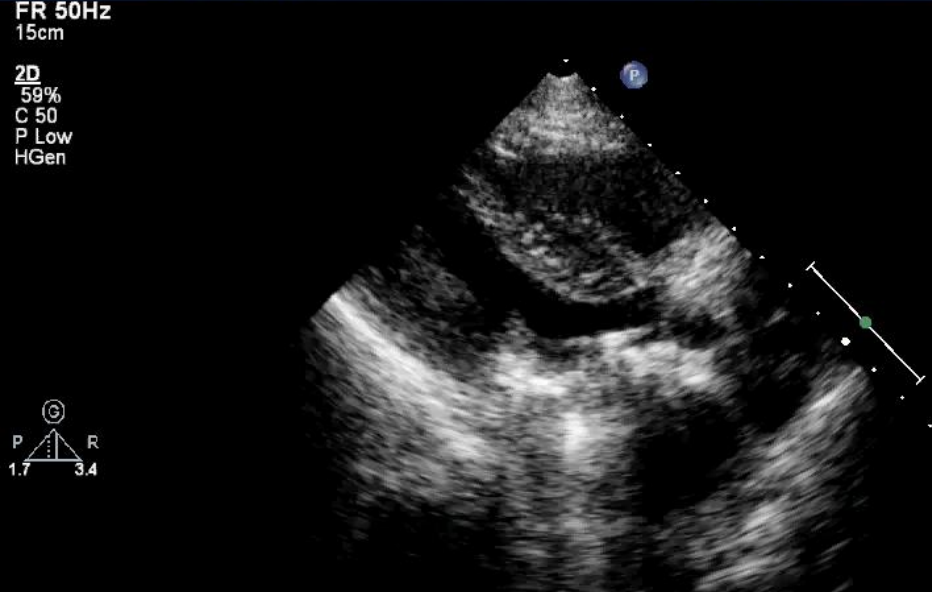
Don Zachariah

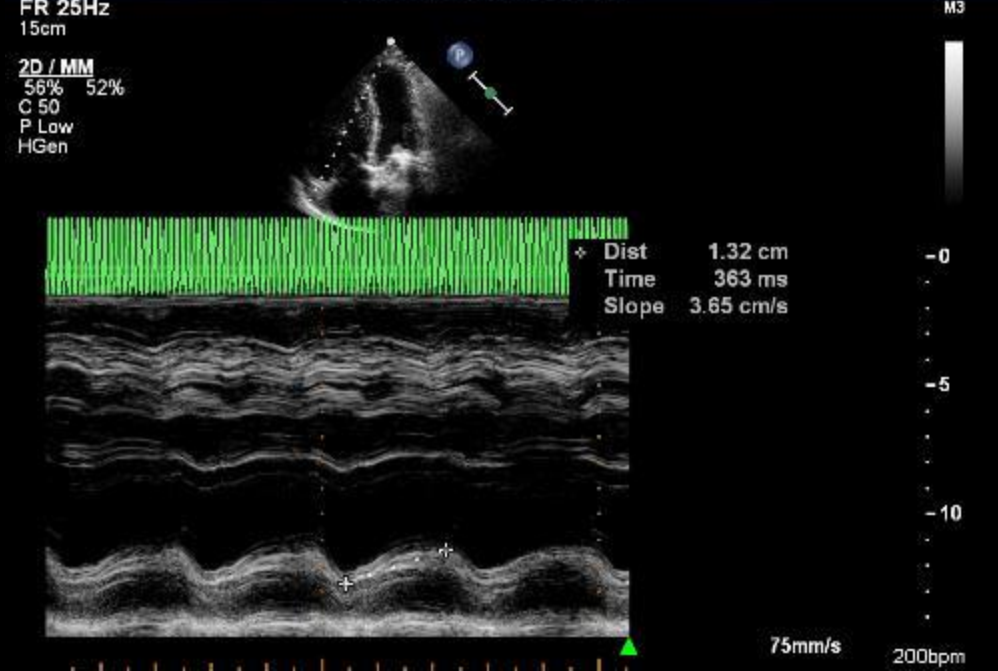
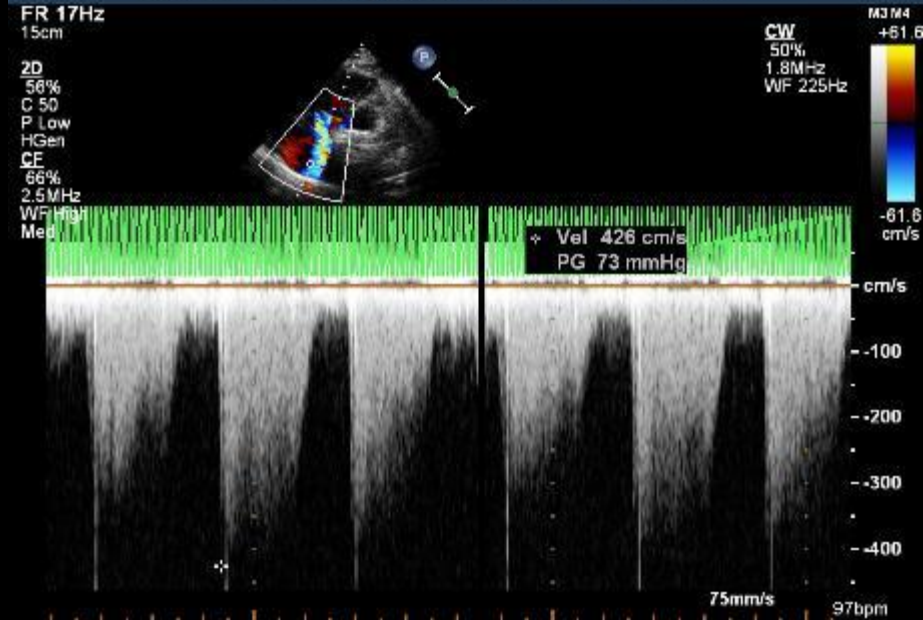
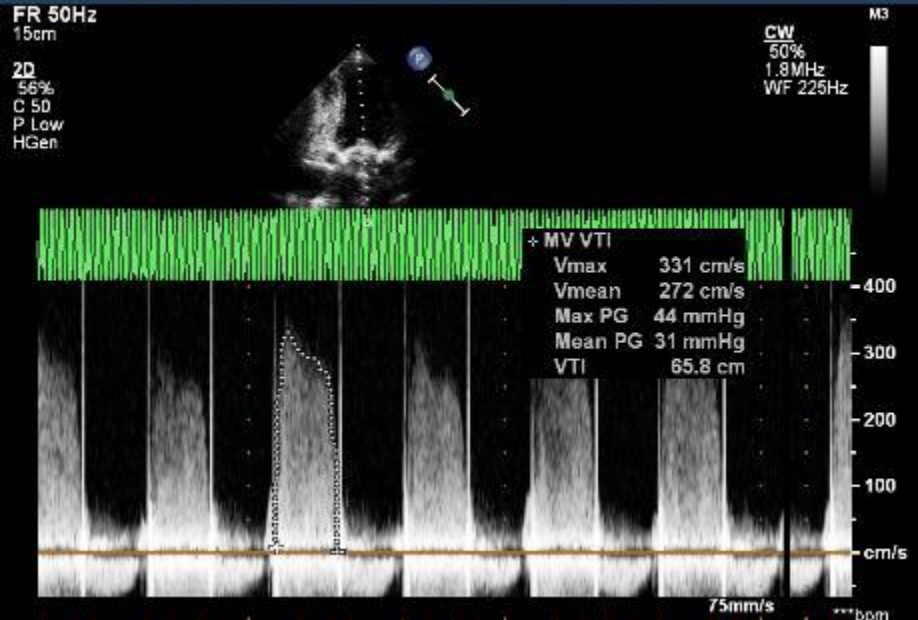
Charlotte Maxeke Johannesburg Academic Hospital



- 30yr old P2G3 at 33weeks gestation
- MVR (mechanical) 2006
- Has been on clexane only regimen throughout pregnancy with Anti Xa level monitoring
- Echo done at 24weeks - normal
- Some history of non compliance when she lost her husband in a car crash
- Noted to have dyspnea which progressively worsened over 2weeks



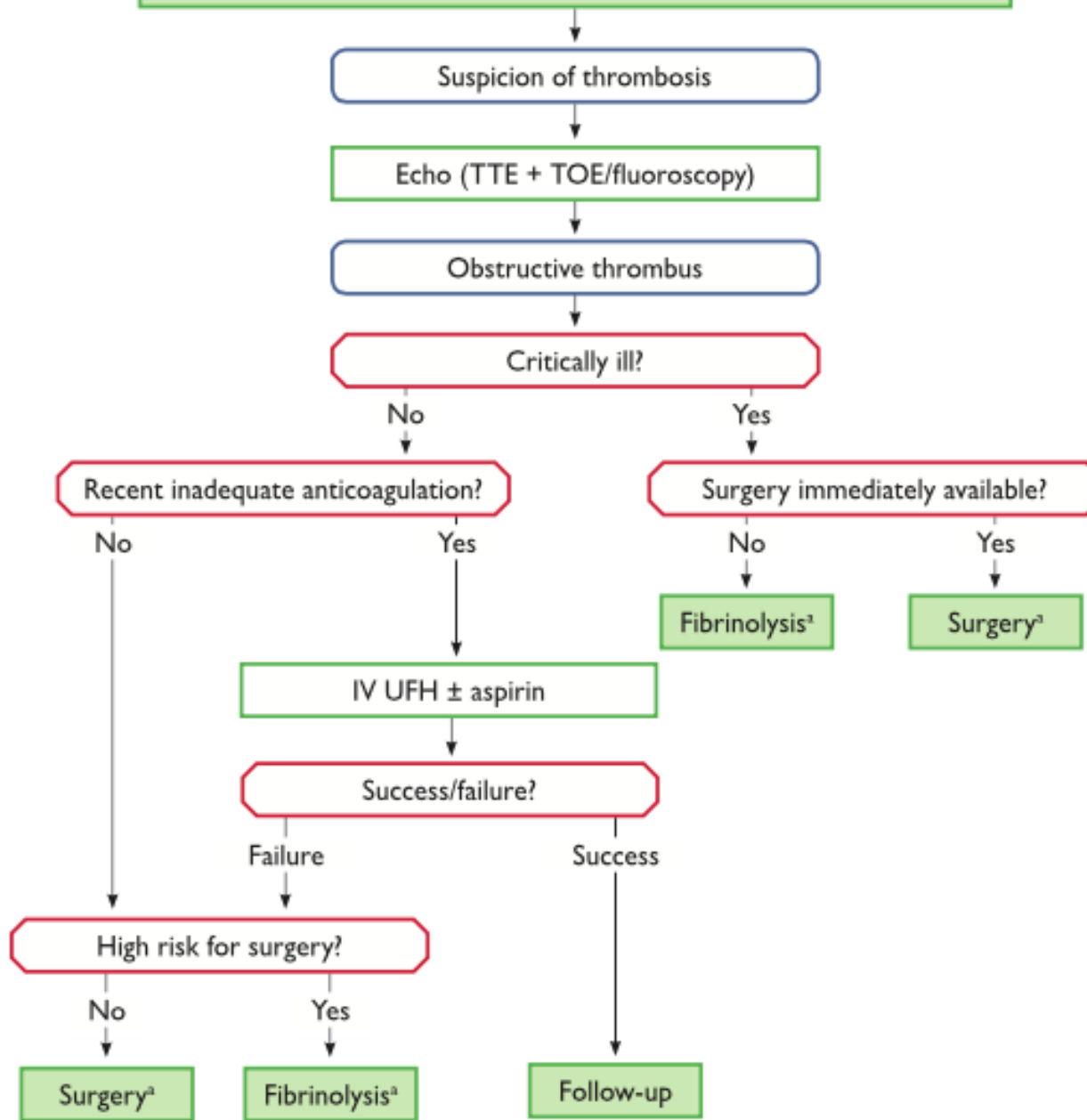




Summary

- 33weeks pregnant
- Valve thrombosis
- Suspicion of infective endocarditis

Management of left-sided obstructive mechanical prosthetic thrombosis




Discussion

- **Surgical correction**
 - C/S first and then MVR
 - Emergency MVR with baby inside
- **Thrombolytic therapy**



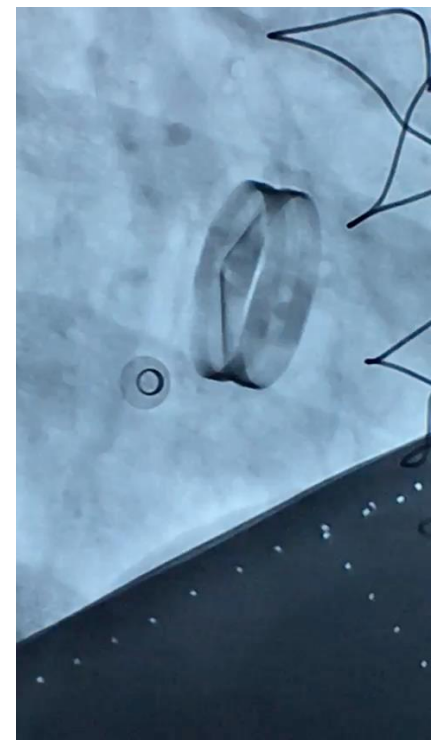
What was done

- Patient refused surgery
- Lytic – actilyse given (50mg)
- Symptomatically the same
- Mean gradient drop from 31mmhg -> 25mmHg
- Fluro done



What was done

- Patient refused surgery
- Lytic – actilyse given (50mg)
- Symptomatically the same
- Mean gradient drop from 31mmhg -> 25mmHg
- Fluro done



- Rethrombolysed
- Developed abruptio placenta
- PV bleeding, DIC
- Needed RCC/ FFP
- Emergency C/S done in CCU
- Patient demised